

# Implantable miniature telescope: Lessons learned

Susan A. Primo, O.D., M.P.H.

Emory Eye Center, Atlanta, Georgia.

## KEYWORDS

Implantable miniature telescope;  
Visual prosthesis;  
Age-related macular degeneration;  
Visual impairment;  
Vision rehabilitation

## Abstract

**BACKGROUND:** The Implantable Miniature Telescope (IMT™) is a telescopic prosthesis that, combined with the optics of the cornea, constitutes an intraocular magnifying system. It is indicated for use in patients with stable, nonfoveal sparing, bilateral, stable, age-related macular degeneration (end-stage) with associated scotomas. The telescope prosthesis is implanted in only one of the patient's eyes. In this way, the implanted eye provides improved visual acuity, and the nonimplanted eye continues to provide peripheral vision for ambulation. Two hundred seventeen patients with end-stage AMD were enrolled in a prospective, multicenter, open-label trial (IMT-002) beginning in 2003. The implanted eye was the worse eye for most patients based on a selection rule set by the U.S. Food and Drug Administration (FDA) protocol; however, in most cases (90%), visual acuity improvement goals were met with the device. This report will retrospectively look at 2 selected patients implanted at the Emory Eye Center in Atlanta as part of that trial to derive lessons for subject and eye selection criteria.

**CASE REPORTS:** Two cases were selected to represent patients' levels of functional success and satisfaction. Determination of their visual and functional outcome at 1-year postimplantation was based on best-corrected visual acuity and the National Eye Institute Visual Functioning Questionnaire 25-Item quality-of-life survey. Four years after implantation, 1 patient continued to use the telescope prosthesis eye for all visual activities; the other patient did not perceive any benefit from the device and continued to primarily use the fellow nonimplanted eye. The benefit of the telescopic prosthesis was most likely accounted for by the level of visual acuity in both eyes postimplantation and eye dominance.

**CONCLUSION:** Proper eye selection chosen for implantation with the telescope prosthesis appears to be an important if not critical factor in determining patient satisfaction for visual processing and functional success. Based on the author's experience with the IMT, optometrists can aid the multidisciplinary team by preoperatively determining which eye, if implanted, offers the optimal potential functional benefit for appropriate candidates.

Optometry 2010;81:86-93

More than 1.75 million Americans are affected by advanced age-related macular degeneration (AMD), defined as choroidal neovascularization (CNV), disciform scar, or geographic atrophy in at least 1 eye; the number of

affected Americans will increase to almost 3 million by the year 2020.<sup>1,2</sup> Despite recent advances in the treatment of CNV, many patients can progress to moderate, severe, or profound visual impairment caused by bilateral central

**Financial disclosure:** Susan A. Primo has no commercial or financial interests associated with the device. The long-term follow-up study was supported by a clinical research trial sponsored by VisionCare Ophthalmic Technologies, Inc.

This research paper was supported in part by NIH NEI Grant EY06360 and an unrestricted grant from Research to Prevent Blindness, Inc.

Corresponding author: Susan A. Primo, O.D., M.P.H., Department of Ophthalmology, Emory University School of Medicine, 1365B Clifton Rd., NE, Atlanta, Georgia 30322.

E-mail: [sprimo@emory.edu](mailto:sprimo@emory.edu)


scotomas that affect both distance and near vision. Therapies for geographic atrophy still remain elusive.

Patients with bilateral central vision loss respond to magnification. Peli<sup>3,4</sup> has described the term *vision multiplexing*, which consists of the brain receiving 2 or more messages (i.e., images) at the same time and having to reconcile them. Several head- and spectacle-mounted low vision devices operate on this principle of bi-ocular multiplexing, including bioptic telescopes. The patient views through a monocular telescope for seeing a magnified image, and simultaneously has the areas not magnified by the telescope viewed by the other eye, i.e., retaining peripheral field for mobility. Similarly, telescope prosthetic devices could function through the concept of bi-ocular multiplexing, whereby the implanted eye delivers the magnified image for improved acuity, and the fellow eye sees the environment outside the telescope-viewed area.

A micro-optical intraocular miniature telescope (IMT<sup>TM</sup>) prosthesis for end-stage AMD (VisionCare Ophthalmic Technologies, Saratoga, CA), designed to reduce the relative size of the scotoma compared with objects in the central visual field, has received CE mark approval in the European Union and is undergoing the U.S. Food and Drug Administration (FDA) pre-marketing approval process in the United States.<sup>5-8</sup> The telescope prosthesis is available in nominal magnifications of 2.2x and 3x and contains 2 micro lenses (front positive lens and back negative lens) in an air-filled glass tube (4 mm in length) that, with the optics of the cornea, constitutes a magnifying system to enlarge retinal images of the central visual field. The prosthesis magnification improves distance or near visual acuity in conjunction with standard spectacle correction for ametropia, presbyopia, or further external magnification.<sup>6,8</sup> The optical components are embedded in a plastic carrier implanted in the capsular bag in the posterior chamber of the eye in place of the eye's crystalline lens after extracapsular cataract surgery or phacoemulsification. The tube is almost entirely in the posterior chamber and protrudes marginally through the pupil, making the device hardly visible to the casual observer and thus cosmetically superior to most distance and near low vision devices (see Figures 1 and 2).

The telescope prosthesis is designed for use in patients with nonfoveal sparing, bilateral, stable (no active CNV or treatment in the previous 6 months), end-stage AMD (geographic atrophy, disciform scar, or both) as determined by the retinal specialist, photos, and fluorescein angiography.<sup>6</sup> Central vision loss must be sufficiently advanced to cause reduced visual acuity of at least 20/80 or worse in the better eye with near normal peripheral vision retained (at least in the nonimplanted eye). The prosthesis is only implanted in 1 of the patient's 2 affected eyes. Thus, the implanted eye provides improved central visual acuity, and the fellow eye continues to provide peripheral vision for safe mobility and navigation.

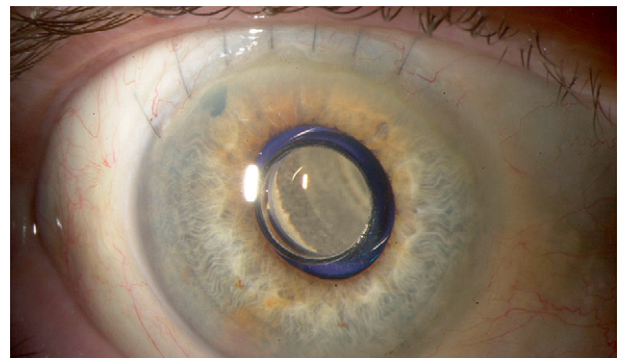
The telescope prosthesis was designed with the following features and purposes:



**Figure 1** Telescope prosthesis for end-stage AMD. The top window is the front of a glass tube that houses 2 wide-angle micro-optical lenses. A blue light restrictor encircles the optical component of the device.

- Depth of field extending from 1 m and beyond, ideal for intermediate distance visual activities. Standard near add spectacles allow for focusing for near vision activities.<sup>6</sup>
- Relatively large external field of view (at least 20° to 24°) depending on device model.<sup>6</sup>
- Allows scanning (of reading materials or other images) using natural eye movements rather than head movements.<sup>4</sup>
- Avoidance of vestibular conflict because of the ability to scan with an eye movement in contrast to head movements.<sup>4,9</sup>
- Available “on-demand” and “hands-free” (i.e., without necessitating locating and manipulation).<sup>4</sup>
- Patient is free from being stereotyped as disabled.
- Psychosocially, the telescope prosthesis is compatible with social interaction (e.g., eye contact and facial expressions).

The telescope prosthesis projects a wide retinal image to maintain visual acuity improvement over the long term



**Figure 2** Telescope prosthesis 6 weeks postimplantation. The high-plus wide-angle lens is seen behind the anterior window, which marginally protrudes through the iris plane. (Courtesy of James Gilman, CRA.)

even in the presence of slow progression of end-stage AMD. The combination of the refractive power of the cornea and the wide-angle micro-optics of the device (and its air spaces) renders the optical power to produce an enlarged and magnified image of the central visual field that is approximately  $53^\circ$  on the central and peripheral retina; the central field is enlarged from 2.2 to 3 times depending on the prosthesis model implanted, making it ideally suited for allowing the patient to recognize images that previously were difficult to see.<sup>8</sup> The angle on the retina of  $53^\circ$  ( $54^\circ$  in the product specifications for the wide angle 3x prosthetic) is achieved as a result of magnification. It is equal to the external forward field of view multiplied by the device magnification factor, i.e.,  $20^\circ \times 2.7x = 54^\circ$  on the retina.

The option of offering additional, supplemental magnification as needed for near or intermediate-specific tasks is retained. If there is further deterioration of the macula and a reduction in vision after implantation, appropriate low to higher plus reading lenses can be utilized to further increase the amount of magnification as needed. These lenses are prescribed in the same way as any higher add would be for low vision patients. Similarly, electronic, handheld and nonoptical devices over and above the IMT can and should be recommended for enhanced achievement of patients' goals.

## Background

The 2 reported patients in this report were selected from the IMT-002 clinical trial for which inclusion/exclusion criteria, safety, and efficacy have been described previously.<sup>6</sup> Background study information is provided in brief as follows. Two-hundred and seventeen (217) patients aged 55 and older with bilateral disciform (no active CNV) or atrophic AMD and best spectacle-corrected visual acuity (BSCVA) 20/80 to 20/800 were enrolled in a prospective, multicenter trial (IMT-002) and is reported elsewhere. Patients were required to demonstrate a 5 letter minimum improvement in BSCVA on the Early Treatment Diabetic Retinopathy Study (ETDRS) chart with an external telescope. Of the 217 enrolled, 206 patients received successful implantation of the telescope prosthesis at 28 centers across the United States. Patients were treated and managed by a multidisciplinary team that included a retina specialist, anterior segment surgeon, and low vision optometrist. The low vision optometrist was affiliated with or had some referral relationship with the site if they were not physically on site.

The method used for determining which eye to implant with the telescope prosthesis for the IMT-002 trial was based primarily on the protocol requirements of the FDA study. If one or both eyes had BSCVA better than 20/200, the telescope prosthesis was implanted in the eye with poorer visual acuity. If both eyes had BSCVA of 20/200 or worse, the investigator and patient chose which eye to implant based on clinical evaluation only (see Appendix 1 for summary of IMT-002 preoperative evaluation protocol).

Per IMT-002 study protocol, 6 visual rehabilitation sessions were conducted during the first 3 months after surgery (weeks 1, 2, 4, 6, 10, and 12). The goal of the sessions was to incorporate the new visual status in everyday activities by providing each patient with the skills to adjust to the new central visual acuity from the telescope prosthesis and used in such a way that optimal function was achieved in minimal time. Outcome measures included change in BSCVA at distance and near (40 and 20 cm), National Eye Institute Visual Functioning Questionnaire-25 (NEI VFQ-25),<sup>10,11</sup> and a modified version of the Activities of Daily Vision Scale (ADVS) scores<sup>12,13</sup> (see Appendix 2 for IMT-002 rehabilitation protocol).

In IMT-002, mean baseline BSCVA was 20/316 at distance and 20/250 at near. At 2 years, distance and near acuity improved 3.15 and 2.9 lines from baseline in the implanted eyes compared with 0.5 and 1.7 lines, respectively, in fellow eyes ( $P < 0.0001$ ).<sup>8</sup> NEI VFQ-25 scores improved significantly from baseline ( $P < 0.01$ ) on 7 of 8 relevant subscales at 1 year (a gain of 5 points or more is considered statistically and clinically significant).<sup>6,14,15</sup> Statistically significant improvements were also observed on the modified ADVS. The telescope prostheses were explanted in 8 of 206 (3.9%) patients because of device failure ( $n = 2$ ), corneal decompensation ( $n = 2$ ), and patient dissatisfaction ( $n = 4$ ). Patient education was extremely important: (1) when near activity low vision devices were required in conjunction with the telescope-implanted eye (the postoperative magnification need was based on many factors such as lighting and desired activity, but, generally speaking, the magnification required was considerably less with the use of a more optimal working distance); (2) to optimize the ability to alternate eye viewing for central and peripheral visual tasks; (3) to understand depth perception cues; and (4) to localize optimal and eccentric viewing position when necessary.

## Description

Of the 206 patients studied in IMT-002, 15 received implants at the Emory Eye Center between March and November 2003. For all of these patients, visual acuity improvement goals were met with the device. In 2007, the author had the opportunity to prospectively study functional parameters in 7 of these patients, as 3 of the original 15 died, 2 moved out of state, 1 was explanted, and 2 declined participation. To understand the outcomes of the 2 patients presented in this report, a brief description of the objectives of this small, prospective study is summarized: (1) to evaluate long-term visual acuity and visual rehabilitation outcome after implantation of a telescope prosthesis in patients with bilateral, untreatable, end-stage AMD including identification of challenges and possible ways for improvement of care and patient selection; (2) to develop postoperative visual rehabilitation recommendations of optometric techniques including optimal determination of magnification for near activities, troubleshooting approaches to mitigate potential

visual symptoms such as environmental considerations (lighting) to reduce glare, contrast sensitivities differences between implanted and fellow eye, and orientation/mobility strategies; (3) to develop occupational therapy rehabilitation approaches to achieve positive outcomes for activities of daily living (ADL), orientation/mobility, eye suppression techniques skills training; and (4) to begin to develop appropriate parameters for preoperative optometric patient selection factors such as patient's goals/expectations, vision disorders, history of low vision device use, and eye selection factors ultimately to determine recommendations for candidacy for implantation.

All patients in this study were seen over 4 visits (12 weeks) and included 4 hours total of in-office occupational therapy utilizing VisionCare's Rehabilitation Training Program, 2 hours of homework exercises per week, and 1 telephone interview. Evaluation in this study included determination of eye dominance as well as glare, contrast sensitivity, and mobility testing. All 7 patients showed reduced contrast sensitivity in the telescopic eye (as compared with the fellow eye) with the Peli-Robson test, glare predominately outside (as described by the patients), and no mobility problems unless the fellow eye was occluded. The author used an internally designed subjective and objective assessment tool to further evaluate other functional parameters. The tool was used in addition to evaluating eye dominance, glare, contrast sensitivity, and mobility as mentioned above; the IMT-002 trial did not formally evaluate any of these parameters.

Of the 7 patients studied, a trend was observed regarding visual acuity, functional success, and eye dominance as it related to apparent patient satisfaction. Three patients ended up with better or nearly equal acuity in the telescope eye versus the fellow nonimplanted eye; however, in only 1 patient was the telescope eye determined to be the dominant eye. This patient (case report 1) had a very successful outcome based on VFQ scores at 12 months in the original IMT-002 trial. A second patient (case 2) did not report any benefit from the device, and his visual acuity in the fellow nonimplanted eye was better than that in the IMT eye. These 2 cases were selected to represent the range of patients' levels of functional success and satisfaction from the time of implantation and are described below.

## Selected case reports

### Patient 1

A 74-year-old white woman presented who had stable exudative AMD for 3 years at the time of implantation. Preoperative visual acuity using the ETDRS chart measured logMAR (logarithm of the minimal angle of resolution) 1.14 (20/275) in the right eye (O.D.) with +1.75 +1.75x01 (eccentric view at 3:00) and 0.92 (20/160<sup>-</sup>) in the left eye (O.S.) with -1.50 +1.50x030 (eccentric view at

9:00). Eccentric viewing positions were observed and documented using clock-face method. She was enrolled in IMT-002 and subsequently underwent a 2.2x telescope prosthesis implantation on March 6, 2003 in the right eye. One-year (12 month) postoperative visual acuity measured 0.58 (20/80<sup>+2</sup>) in the telescopic right eye (O.D.) with +0.50 +1.75x010 and 1.06 (20/200) in the fellow left eye (O.S.) with -1.00 +1.25x030. Eccentric viewing positions were maintained and unchanged. Visual acuity improved much better than predicted with the IMT magnification power, and the difference may have been because of the removal of the cataract.<sup>8</sup> The 12-month VFQ-25 composite scores showed a 17-point gain. Acuity gains remained at 2 years.

Four-year follow-up study was performed looking at further functional aspects. Visual acuities measured telescopic right eye (O.D.) 0.6 (20/80) with +.50 +1.50x005 and fellow left eye (O.S.) 0.9 (20/160) with -1.50 +1.50x030. Eccentric viewing positions were maintained and unchanged. Contrast sensitivity measure 0.75 log units in the telescopic right eye and 1.20 in the fellow eye.

With a +7.00 diopters (D) add in the telescopic eye, the patient could read 1M (Sloan notation) at 5 to 6 inches. Sensory dominance testing utilizing Polaroid filters and mirror (patient looking in a mirror with Polaroid glasses and stating which eye is visible) found that she displayed dominance in her telescopic right eye. It was also determined that she could use each eye independently well by alternating back and forth through a series of occupational therapy exercises and training.

### Patient 2

A 74-year-old white man presented who had nonexudative AMD for 4 years at the time of implantation. Preoperative visual acuity measured O.D. 1.36 (20/400) with +0.25 +1.00x180 (eccentric view position at 3:00) and O.S. 0.82 (20/125<sup>-2</sup>) with -.25 +1.75x004 (eccentric viewing position at 9:00). He was enrolled in IMT-002 and subsequently underwent a 2.2x telescope prosthesis implantation on June 12, 2003, in the right eye. One-year postoperative visual acuity measured 0.78 (20/125<sup>+</sup>) in the telescopic right eye with +.25+.25x030 and .82 (20/125<sup>-2</sup>) in the fellow left eye with -0.25 +1.25x180. Eccentric viewing positions were maintained and unchanged. The 12-month VFQ-25 composite scores showed a 6-point loss. Acuity gains remained at 2 years.

Four-year follow-up study found continued worse acuity in the telescopic right eye (O.D.) at 0.9 (20/160) with +1.00 sphere and fellow left eye (O.S.) 0.8 (20/125) with -1.00 +1.50x180. Contrast sensitivity measured 0.75 log units in the telescope eye and 1.05 in the fellow eye.

Near visual acuities measured O.D. 1.6 M with +10.00 D add at 4 inches and O.S. 1.3M with +10.00D add at 4 inches. Sensory dominance testing found the nonimplanted fellow left eye was dominant. The patient reported he used the

**Table 1** VFQ results and visual acuity comparison of implanted eye versus fellow eye at 12 months

Patient	Implanted eye VA increase	Eye selection (telescope eye VA vs. fellow eye)	VFQ	Comment
1	+5.6 lines better	+5 lines better	+17 points	Ideal for implantation
2	+5.8 lines better	-2.2 lines worse	-6 points	Eye selection issue

fellow left eye for watching television and all near point activities. Additionally, he felt that he could use the telescopic right eye for visual tasks only if the fellow left eye was occluded (*see* Table 1 for case report highlights).

## Discussion

Given both advantages and limitations of the device, the author believes that utility of the improved visual acuity provided by the telescope prosthesis (as demonstrated in patient 1) is based on the telescope-implanted eye becoming the better-seeing eye for the patient (or “even better-seeing” eye if the prosthesis is implanted in an already better-seeing, but visually impaired eye). This allows patients to see more in their central visual field and better than their contralateral eye, which should translate to improved performance in both specific tasks and psychosocial aspects of daily life demonstrated through quality-of-life instruments (modified ADVS and NEI-VFQ) and other functional parameters as assessed by the author’s internally designed tool. Thus, careful screening in choosing the eye for telescope implantation will likely help achieve the proper postoperative visual status as is shown in the patients presented here.

There were several functional parameters that were not measured in the original IMT-002 trial, which the author had the opportunity to assess. In particular, no eye dominance was determined before implantation, nor was there a preoperative contrast sensitivity measurement. However, evaluation at 4 years out clearly demonstrated a “parallel” between the VFQ gains or losses at 12 months and the author’s assessment 4 years later, translating into making some inferences about eye selection and potential predictors of success for implantation.

As mentioned previously, eye selection for implantation for the IMT-002 trial was based primarily on the protocol requirements of the FDA study. There were some clear pros and cons to this method, but it was not possible to alter the protocol. For example, the worse-seeing eye was implanted in most cases with little to no assessment as to how the individual would function after implantation. Currently being used in a clinical trial in the United Kingdom (IMT-UK), an external telescope simulator (ETS) has been developed that more accurately simulates the optical parameters of the telescope prosthesis and provides an end-stage AMD candidate with a visual experience that mimics the implant. The unique dimensions of the ETS allow simulation of the magnification, relative scotoma minimization, field of view, and retinal illumination associated

with the implantable telescope versus demonstration using an external standard telescope which was used in IMT-002 described in Appendix 1. In addition, a 0.6 log unit filter (40% transmission) is available to place over the ETS to demonstrate the reduced contrast presumably induced from the prosthesis. Suitable candidates given an opportunity to use the ETS with one eye can better understand what their visual status may be like postoperatively and better align their postoperative visual expectations; they must also understand the need for visual rehabilitation associated with implantation.

During the simulation, the candidate should first respond to magnification—either the 2.2x or 3x power. Next, the practitioner should discuss with the candidate the relatively wide field of view of the ETS/implanted device versus an external telescope, the differences in illumination inherent with the telescope (demonstrated with the filter described above), and the relative scotoma minimization. The practitioner can use the ETS to visually demonstrate these important factors and as a preoperative assessment tool for potential visual acuity improvement. Select patients for whom the features of the telescope prosthesis would improve their quality of life (i.e., use of natural eye movements, unlimited effective field of view, social interaction, avoidance of vestibular conflict, hands-free and on-demand use) would have appropriate expectations set by the practitioner through this process.

The ETS plays an important role in an eye selection algorithm that is currently being used in the U.K. trial. There should be a conscious determination and systematic protocol to determine best eye for implantation based on visual acuity responses to the ETS. Both patient and doctor can determine which eye might be best suited for implantation based on the patient’s self assessment and level of comfort. A similar decision is often made when prescribing monocular low vision devices, such as spectacle-mounted telescopes and microscopes, as well as when fitting monovision contact lenses or intraocular lens implantation after refractive or cataract surgery. Typically, the dominant or better-seeing eye is used for distance viewing with the various modalities mentioned above. Therefore, it also makes sense that a well thought out, similar systematic approach to proper eye selection would be critical to patient satisfaction and success with the telescope prosthesis. Dominance testing might include a combination of sensory, aiming, and mobility evaluations to cover a thorough approach. It is beyond the scope of this report to discuss specifically, but the U.K. trial is demonstrating success extensively evaluating and confirming eye dominance as

part of the eye selection strategy. To demonstrate loss of peripheral vision, a tolerance assessment might be done by patching the target implant eye preoperatively, thus instructing the candidate to compensate by frequent head turning/scanning in the direction of the patched eye.

Commonly, most questions raised regarding the permanent implantation of a telescope prosthesis revolve around a patient's ability to adjust to the possible presence of diplopia, image size differences (aniseikonia), and field of view restriction—all traditionally considered challenges to mobility. Indeed, many of these issues surfaced immediately postoperatively in varying degrees and were primarily managed through the 6 vision rehabilitation sessions. Mobility was not an ongoing issue or concern to the patients in the author's study, but it is important to inform prospective patients that it may take several months to gain a comfort level and significant reduction of the symptoms described above because of the visual status change. Additionally, patients require continuing care by vision rehabilitation specialists for monitoring visual and functional status, determination of additional magnification, and add for visual activities (less is needed post-IMT) and glare control. As hypothesized in this report, proper preoperative eye selection is likely to be an important factor for successful outcomes.

Of the patients presented here, patient 1 achieved a quality-of-life benefit as reported by clinically meaningful<sup>14,15</sup> improvement on her NEI VFQ score change; this patient had her postoperative telescope-eye visual acuity surpass her fellow eye visual acuity. Ideally, better visual acuity in the telescope eye (if it were also the dominant eye) compared to the fellow eye would likely be more beneficial to keep the patient from needing to work through any ocular rivalry between eyes. Patient 2 did not have his telescope-eye visual acuity achieve the fellow eye visual acuity level, nor did it test as the dominant eye 4 years out. Also, this patient did not show the beneficial VFQ change of the other patient; all these factors likely attributed to his dissatisfaction. The author believes that the 2 patients presented are representative of lessons learned from the clinical trial regarding eye selection as well as some of the other parameters mentioned and can lend some important recommendations to success of the device.

## Conclusion

From the author's experience and evaluation, end-stage AMD candidates for this telescope prosthesis can benefit from careful eye selection screening to ensure the telescope-implanted eye will be in the patient's better-seeing (and dominant) eye after surgery. Proper eye selection as well as evaluation of the other parameters may assure the practitioner that the patient will have an optimal situation to incorporate the new visual status into everyday activities and enjoy an improvement in quality of life. Unlike most medical and surgical therapies, the telescope procedure affords a unique opportunity, with an external telescope

simulator, to preoperatively assess the potential benefits and trade-offs for each individual patient that meet the medical and visual acuity criteria. Patient satisfaction with the telescope prosthesis remains a multifaceted process, including eye selection factors such as determining eye dominance, performing contrast sensitivity and mobility testing, and assessing a patient's psychosocial profile through visual function questionnaires, cognitive evaluation, and depression screens; these are all factors necessitating a comprehensive approach to patient selection and management for alignment of person-specific and technology-specific characteristics to expectations and goals for the prosthesis. As described in this report, it is believed that the optometrist can play a key role in aiding successful outcomes with this therapy for appropriate visually impaired patients suffering from end-stage AMD.

## References

1. Prevalence of age-related macular degeneration in the United States. *Arch Ophthalmol* 2004;122:564-72.
2. Age-Related Disease Study Research Group. Potential health impact of age-related eye disease study results. AREDS report no. 11. *Arch Ophthalmol* 2003;121:1621-4.
3. Peli E. Vision Multiplexing: An engineering approach to vision rehabilitation device development. *Optom Vis Sci* 2001;78:304-15.
4. Peli E. The optical functional advantages of an intraocular low-vision telescope. *Optom Vis Sci* 2002;79:225-33.
5. Lane SS, Kuppermann BD, Fine IH, et al. A prospective multicenter clinical trial to evaluate the safety and effectiveness of the implantable miniature telescope. *Am J Ophthalmol* 2004;137:993-1001.
6. Hudson HL, Lane SS, Heier JS, et al. Implantable miniature telescope for the treatment of visual acuity loss resulting from end-stage age-related macular degeneration: 1-year results. *Ophthalmology* 2006;113:1987-2001.
7. Lane SS, Kuppermann BD. The implantable miniature telescope for macular degeneration. *Curr Opin Ophthalmol* 2006;17:94-8.
8. Hudson HL, Stulting RD, Heier JS, et al. Implantable telescope for end-stage age-related macular degeneration: long-term visual acuity and safety outcomes. *Am J Ophthalmol* 2008;146:664-73.
9. Demer JL, Porter FI, Goldberg J, et al. Adaptation to telescopic spectacles: Vestibulo-ocular reflex plasticity. *Invest Ophthalmol Vis Sci* 1989;30:159-70.
10. Mangione CM, Lee PP, Gutierrez PR, et al. Development of the 25-item NEI Vision Function Questionnaire. *Arch Ophthalmol* 2001;119:1050-8.
11. Owen CG, Rudnicka AR, Smeeth L, et al. Is the NEI-VFQ-25 a useful tool in identifying visual impairment in the elderly? *BMC Ophthalmol* 2006;6:24.
12. Mangione CM, Phillips RS, Seddon JM, et al. Development of the 'Activities of Daily Vision Scale'. A measure of visual functional status. *Med Care* 1992;30:1111-26.
13. Pesudovs K, Garamendi E, Keeves JP, et al. The Activities of Daily Vision Scale for Cataract Surgery Outcomes: re-evaluations validity with rasch analysis. *Invest Ophthalmol Vis Sci* 2003;44:2892-9.
14. Submacular Surgery Trials Research Group. Evaluation of minimum clinically meaningful changes in scores on the National Eye Institute Visual Function Questionnaire (NEI-VFQ) SST Report Number 19. *Ophthalmic Epidemiol* 2007;14:205-15.
15. Globe DR, Wu J, Azen SP, et al. for the Los Angeles Latino Eye Study Group. The impact of visual impairment on self-reported visual functioning in Latinos: The Los Angeles Latino Eye Study. *Ophthalmology* 2004;111:1141-9.

## Appendix 1: Preoperative External Telescope Evaluation (IMT-002 Study Protocol)

### STEP ACTION:

1. With the patient sitting in a chair, the external wide angle 3.0x telescope is placed over the patient's distance correction in a trial frame. It should be communicated to the patient that the external telescope is intended to provide the patient with a simulated experience of the magnification, clarity, and visual field (slightly less than the corresponding WA 2.2x or 3.0x IMT) that can be expected with the IMT.
2. Each eye should be tested individually. The fellow eye should be covered with a paddle, and then uncovered and the patient questioned on preference for one eye over the other. It is important to gauge the patient's ability to use the telescope with the fellow eye not covered. The patient should be able to use the telescope with the fellow eye uncovered. Failure to do so may indicate strong dominance of the second eye; this should be considered in the determination of the eye to be selected for surgery.
3. At a distance of approximately 3 meters, the patient should be asked to look at another person's face while an assistant repeatedly puts on and takes off the telescopes. The patient is asked to compare vision with each telescope. It is important to determine what the patient hopes to achieve through implantation of the IMT and to ensure that these goals are within the anticipated improvement in vision that may be provided by the device.
4. This testing should be repeated for the 2.2x telescope.
5. If the patient achieves a 5-letter improvement in visual acuity with either or both of the external telescopes, he/she is a candidate for implantation, and should be given external telescopes to take home and use in practice sessions for at least 3 days. Patients should be instructed to attempt daily tasks and activities such as watching television (from 2 to 3 meters), making coffee, reading, washing hands, etc., while wearing the external telescope(s) in order to provide the patient with a simulation of the visual acuity that may be achieved with the IMT.
6. For safety reasons, the patient should be trained in the use of the telescope while he/she practices walking. They should NOT be allowed to walk about unassisted until they have grown accustomed to the use of the telescope.
7. The patient should return for examination after this in-home trial with the external telescopes. If it is determined that the patient is interested in participating in the study, ETDRS visual acuity should be measured using both external telescopes (refer to [Appendix 2](#) for methods for refraction and ETDRS acuity). The patient must achieve a five-letter or greater improvement in distance visual acuity with at least one of the telescopes to be a candidate for IMT implant. Data should be collected and recorded on the use of both external telescopes regardless of which is preferred by the patient.
8. If the patient has BCVA better than 20/200 in either eye, the eye with worse visual acuity will be designated for implantation.
9. If BCVA is equal to or worse than 20/200, or if visual acuity is the same in both eyes, the choice of the eye to be implanted is left to the discretion of the physician and patient. NOTE: Patients with an intraocular lens in one eye may have the IMT implanted only in the other eye.

## Appendix 2: Rehabilitation Checklist (IMT-002 Study Protocol)

<b>Rehabilitation Basics</b>	
<b>Visual Skills</b>	Localizing, Fixating, Scanning, Tracing and Tracking
<b>Gradual Vision Practice</b>	<ul style="list-style-type: none"> <li>● Recognizing large static objects.</li> <li>● Observing moving targets.</li> <li>● Walking while looking at stationary targets.</li> <li>● Walking while looking at moving targets.</li> </ul>
<b>Rehabilitation Program</b>	<p><b>1 to 2 Weeks Postoperative–Distance Vision–TV Watching</b></p> <ul style="list-style-type: none"> <li>● Use refraction correction (+/- fellow eye patching).</li> <li>● Practice at 2 to 3 meters. Assure light dimming for contrast enhancement.</li> <li>● Practice 3 times a day (5 minutes each gradually increasing to 20 minutes).</li> <li>● Ask patients to describe sight with operated eye (emphasize it is used).</li> </ul> <p><b>2 to 3 Weeks Postoperative–Distance &amp; Intermediate Vision</b></p> <ul style="list-style-type: none"> <li>● Use updated refraction correction (+/- fellow eye patching).</li> <li>● Continue TV watching practice (3 times a day, 20 minutes each).</li> <li>● Start outdoor practice in quiet familiar place (sunglasses/patching if needed).</li> <li>● Assess the need for refraction correction.</li> <li>● Create a personal list of basic intermediate activities according to patient's interests (e.g., playing cards, painting, arranging flowers and preparing meals).</li> <li>● Start practicing intermediate activities (with high illumination). Identify difficult stages for each task and practice until improvement is achieved.</li> </ul> <p><b>3 to 4 Weeks Postoperative (and following sessions)–Distance, Intermediate, and Near Vision</b></p> <ul style="list-style-type: none"> <li>● Use updated refraction correction (+/- fellow eye patching).</li> <li>● Continue TV watching practice (3 times a day, 20 minutes each).</li> <li>● Continue outdoors practice (in street or mall, with sunglasses or patching if needed).</li> <li>● Continue practicing intermediate activities, emphasizing practice of difficult stages.</li> <li>● Reading Program: Practice using adequate near correction (if needed, patch fellow eye). <ul style="list-style-type: none"> <li>○ Assure high illumination</li> <li>○ Use adequate print size</li> <li>○ Create a personal calibration text, which will serve for each home reading session</li> <li>○ Assure stable text positioning</li> <li>○ Teach patients to use thumb tracking technique</li> </ul> </li> </ul> <p><b>Reading at home is an essential part of rehabilitation. A family member should monitor reading (high illumination, distance adjustment). Practice 3 times a day. At first only 5 minutes per session, gradually increasing to 20 minutes.</b></p>
<b>Binocular Rehabilitation</b>	Repeat practice assessment and binocular preference every session.